



# Toenail Trouble Part 2

Common Toenail Problems

Paul Gabriel Scullion  
Podiatric Surgeon

## SOME COMMON TOENAIL PROBLEMS DUE TO TRAUMA

Toenails will endure a variety of stresses and strains in their normal use throughout your life. Keeping in mind that three out of four people will develop a foot problem at some stage in their life, a substantial number of these foot problems will involve the toenails.

Should you suffer from any of the following conditions then seek out the professional help of a skilled chiropodist / podiatrist for your foot healthcare.

### INVOLUTED TOENAIL

Involuted toenails are where the edges only curve downwards. This shape, in conjunction with tight footwear, has the tendency to deliver excessive pressure into the soft border of skin along the sulcus of the nail. Excessive pressure in this location will produce the tendency for hard skin (**callus**) to form. In cases of localised high-pressure very compact, deep and painful hard skin (**corns**) may form (Fig 5). And on rare occasions the skin may even breakdown completely and an open sore (**ulcer**) may form.

### TREATMENT

Cutting a V into the free edge of any ingrown toenail is NOT the answer. This just tears holes in your socks and catches in the bedclothes.

As with all forefoot problems the easiest intervention is to always ensure the toes are correctly accommodated in a comfortable fitted pair of shoes. If tight and restrictive shoes are continually worn then your problem will not respond to the most conservative forms of treatment.

I use specialised surgical instruments that both reduce the thickness of the downward curved nail and also gently remove small sections of the nail plate at its border to allow easy access to the sulcus. With the nail sulcus now freed any callus or corn formation can be painlessly cleared away.

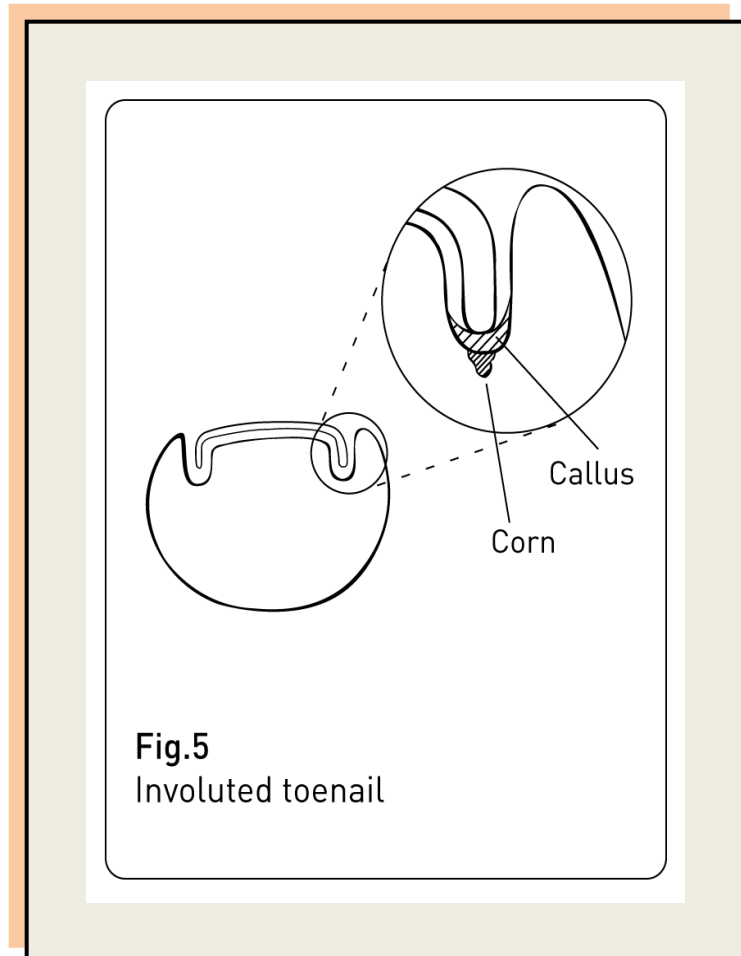
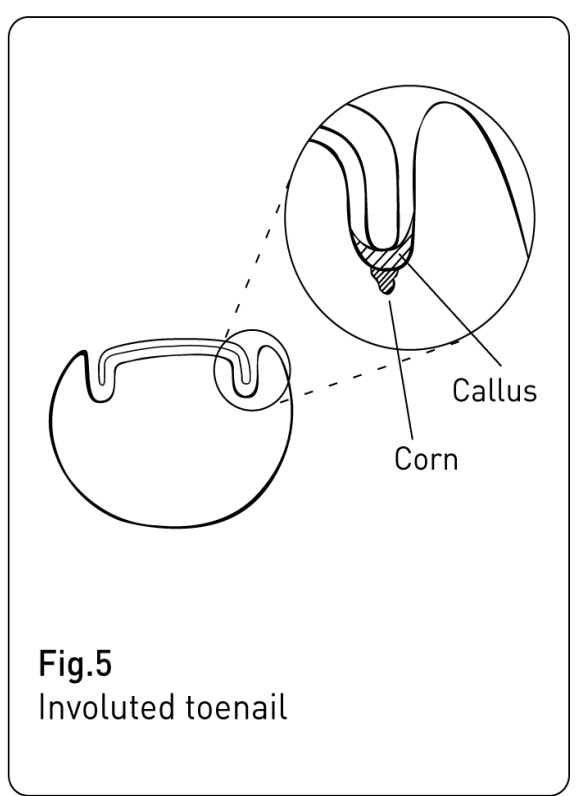


Fig.5  
Involuted toenail



**Fig.5**  
Involved toenail

## INVOLUTED TOENAIL

continued

Treatment like this is NOT a major operation and can be performed in a matter of seconds in the comfort of your practitioner's clinic. On its own, a treatment like this can provide instant and sustained relief of your symptoms. I sometimes apply a topical long-term pain relieving medication to the sulcus to maintain this relief of symptoms.

If the freed nail border reveals an ulcer formation then this condition usually heals in a few days with the assistance of a warm saline footbath routine followed by the application of a powerful antiseptic ointment to the nail border to prevent a bacterial infection becoming established.

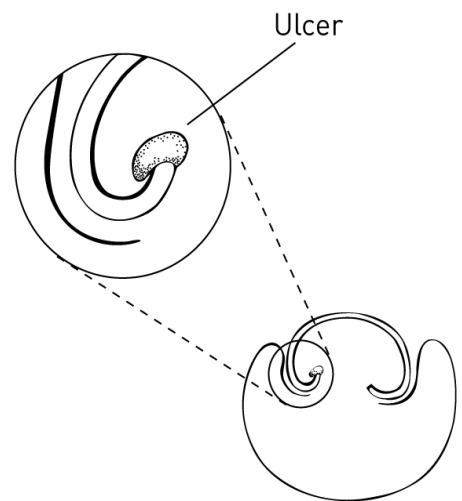
With comfort now re-established in your toe, periodic professional treatment like this can keep you quite happy resulting in you living with your involuted toenails. However, in some instances specialised surgical intervention may be warranted to resolve particularly troublesome involuted toenails. (See **Classic Ingrown Toenail**)

## CONVOLUTED TOENAILS

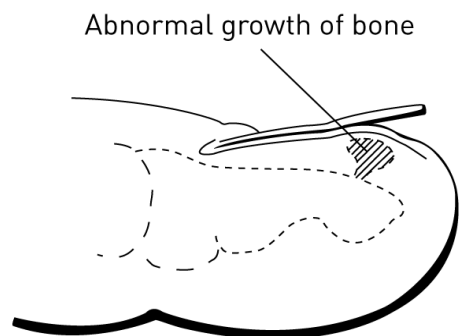
Convoluted toenails are where the nail plate tends to roll up into itself (Fig 6). They can resemble a poorly constructed hand-made cigar. Grossly deformed nails like this can be due to an abnormal bony outgrowth within the toe (**subungual exostosis** Fig 7). But are more often caused by a past history of a severe injury to the nail-germinating matrix.

## TREATMENT

Convoluted toenails require a careful trimming technique because of the bud of sensitive pinched nail bed protruding from under the nail plate. Similar problems to that of involuted toenail can occur. So the development of hard skin and corns along the nail border also happens. Treatment is not too dissimilar to that for involuted toenail. However, due to increased nail bulk and strangulation of nail bed tissue, ulcer formation is more commonly seen with this condition. Again, for the problematic convoluted toenail, surgical intervention can be a better method for resolving this condition in the long-term.



**Fig.6**  
Convoluted toenail



**Fig.7**  
Subungual exostosis

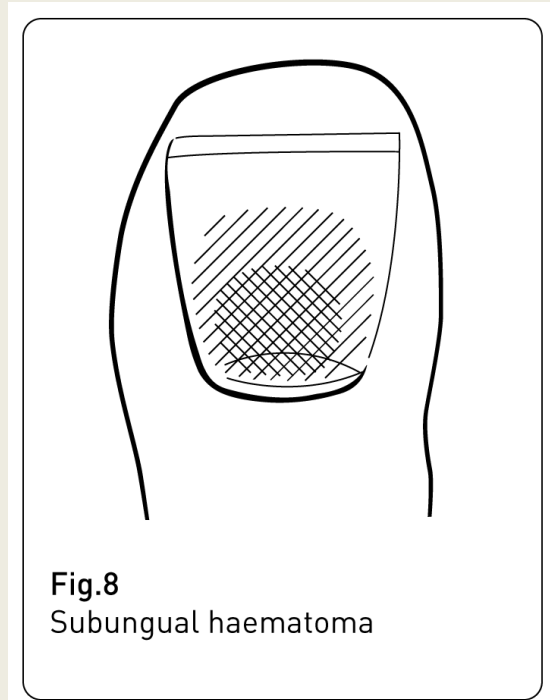
## **BLOOD BENEATH THE NAIL PLATE (ACUTE SUBUNGUAL HAEMATOMA)**

This condition is usually seen following a severe blow to the toe (Fig 8). Something heavy might have dropped on the toe or the toe might have accidentally struck a solid object. Whatever the reason the toe would need treatment within a two-hour period if the nail is to have a chance at being saved. And, where suspected, the toe should be X-rayed to see if the bones might have been fractured.

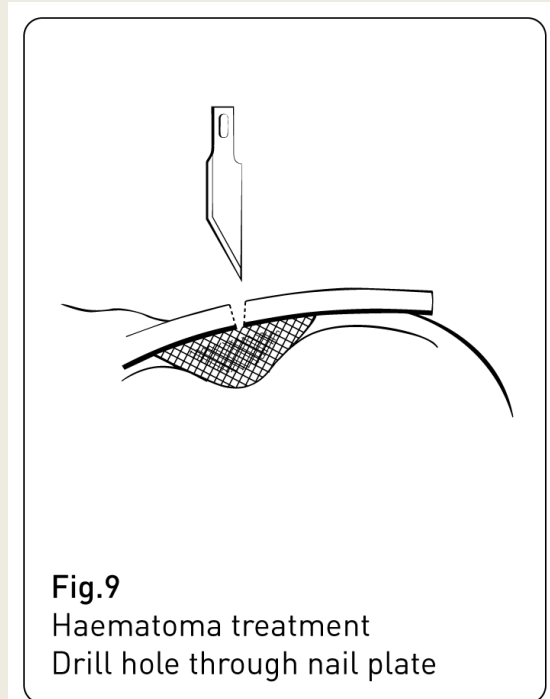
### **TREATMENT**

Emergency treatment (within 2hrs) involves using a scalpel to drill a small hole into the nail plate to release the accumulated pocket of blood (Fig 9). This will immediately improve the comfort of the toe and, since there are no nerve endings within the nail plate, the actual procedure is surprisingly comfortable.

If the injured nail plate is not treated and the blood is allowed to accumulate then it will further work its way under the nail plate. This blood will clot resulting in the nail turning black and eventually separating and falling off. A new toenail will always grow to replace the old one but this new nail may develop in a deformed fashion.



**Fig.8**  
Subungual haematoma



**Fig.9**  
Haematoma treatment  
Drill hole through nail plate

## CLASSIC INGROWN TOENAIL (Onychocryptosis)

This disorder is one of the most excruciatingly painful conditions a human can endure. In my experience the cure is surgical treatment. The pain experienced ranks up there with labour pains in women, toothache and slipped disc. Just ask anyone who has had this condition with someone having inadvertently stepped on it.

Infected ingrown toenail for the most part is a self-inflicted condition. People, who are into self-treatment for involuted and convoluted toenails, by digging down the border of the toenail, may often get away with it. Unfortunately, infected ingrown toenail can happen to the unlucky self-treated.

A sharp point (**spickule**) of toenail can be the end result of poor self-treatment (Fig 10). As the toenail slowly grows out then this spickule cuts into the sensitive flesh of the nail border. The toe becomes very painful, swollen, red and hot. On occasions a discharge of pus will develop and in severe cases a small “strawberry” of tissue will form (**granulation tissue** Fig 11). At this stage two definite disease processes have begun; **Infection** and **foreign body reaction**.

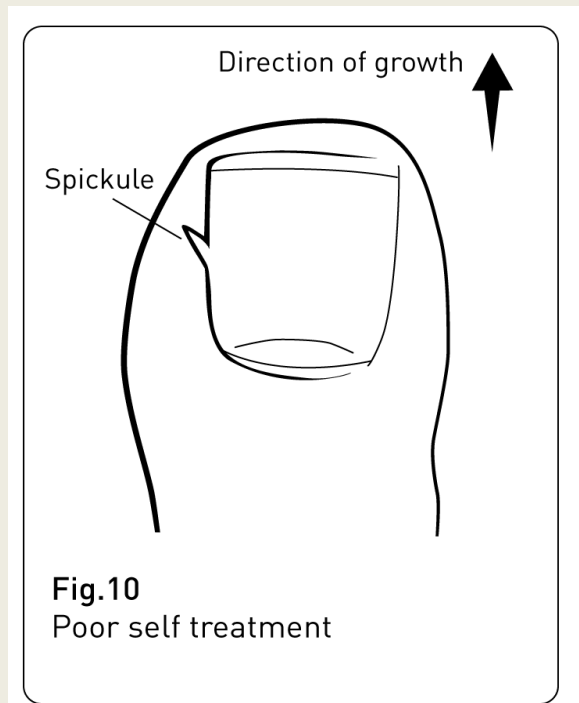


Fig.10  
Poor self treatment

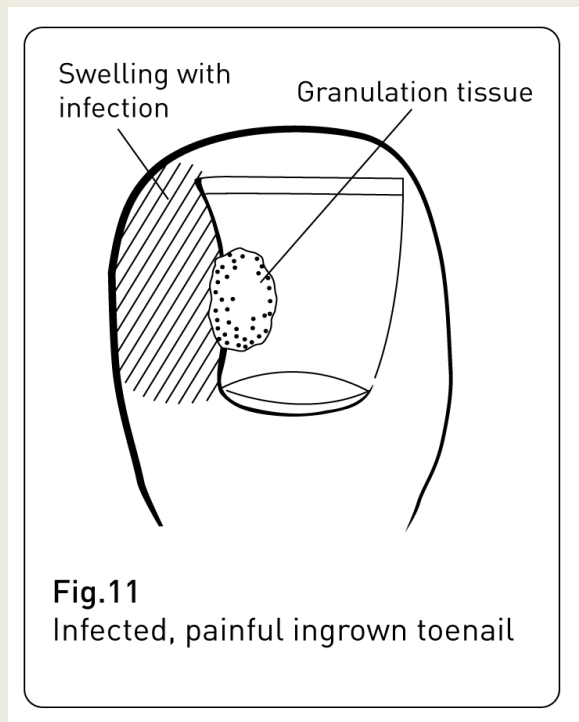


Fig.11  
Infected, painful ingrown toenail

## **INFECTION AND FOREIGN BODY REACTION**

If an ingrown toenail is simply viewed as nothing more than an infection or nothing more than a foreign body reaction on their own, then even the most experienced surgeon can be defeated by this troublesome complaint.

For example, I have performed surgery on a number of patients who have received multiple courses of antibiotics by their family doctor in a failed attempt to try and treat this stubborn condition. It was obvious that their doctor was viewing the condition as just an infection.

Conversely, I have also seen patients who have been assured by their chiropodist that the spicule causing the foreign body reaction has been removed, only to present to my office with pus still oozing from the toenail demonstrating clearly the infection has not been addressed.

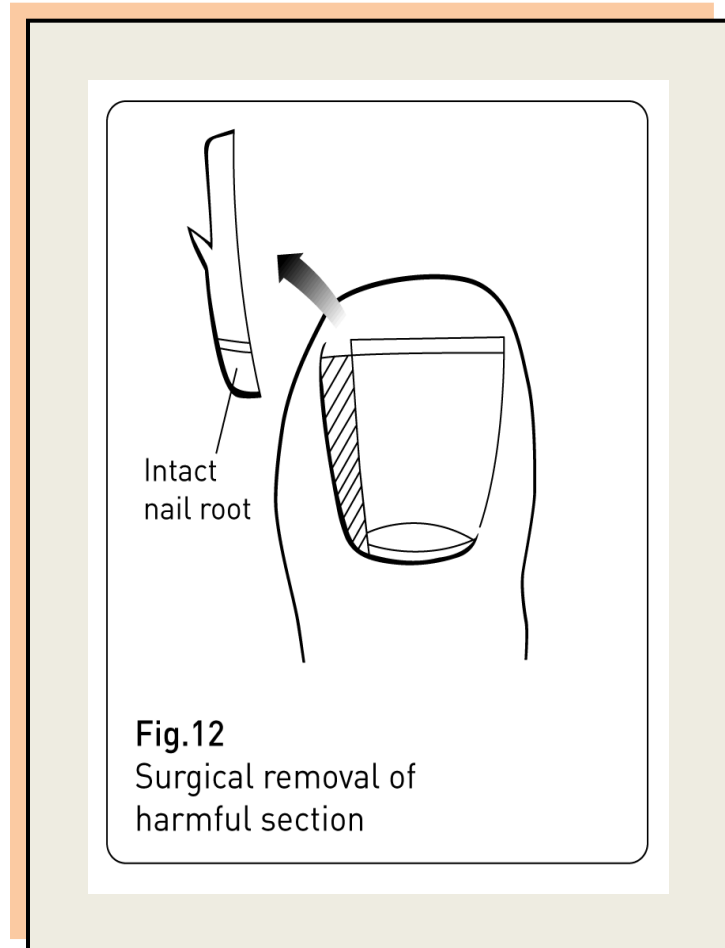
When the processes of infection and foreign body reaction are fully addressed only then is curative surgical treatment for ingrown toenail successful. **Chemical destruction of the nail bed** treats both the infection and the foreign body reaction by permanently removing the offending nail. In a recently published scientific paper the chemical destruction of the nail bed technique was deemed to have a success rate in the high 90% range. Another technique, **surgical excision of the nail bed**, was demonstrated to have a success rate **as low as 50%**.

## TREATMENT

Chemical destruction of the nail bed using 80% strength phenol, is my surgical procedure of choice for problem ingrown toenails. With careful selection of candidate, all instrumentation is sterilised and the foot is prepared with a surgical scrub. A local anaesthetic is introduced to the base of the toe. This gives profound numbness to the toe and nail plate for up to two hours.

A rubber bandage (**tourniquet**) is applied to the toe in such a manner as to squeeze the blood out of the toe and back into the body. This renders the toe white and bloodless for a controlled period of time. The application of a tourniquet like this allows for a clear view of the surgical site. The full operation takes less than 15 minutes and falls well within safe margins for circulation to be temporarily cut off from a healthy digit.

The toe is carefully checked for total numbness and then attention is drawn to the affected nail border. A specialised surgical instrument is introduced to gently free the soft tissues attached to the top of the nail plate. A cut is made at the free edge of the toenail to allow the insertion of a fine surgical chisel. This instrument is then pushed along the nail plate, under the soft tissue fold and down through the germinating matrix. This incision frees the troublesome section of nail, which is removed using a fine clamping forceps (Fig 12).

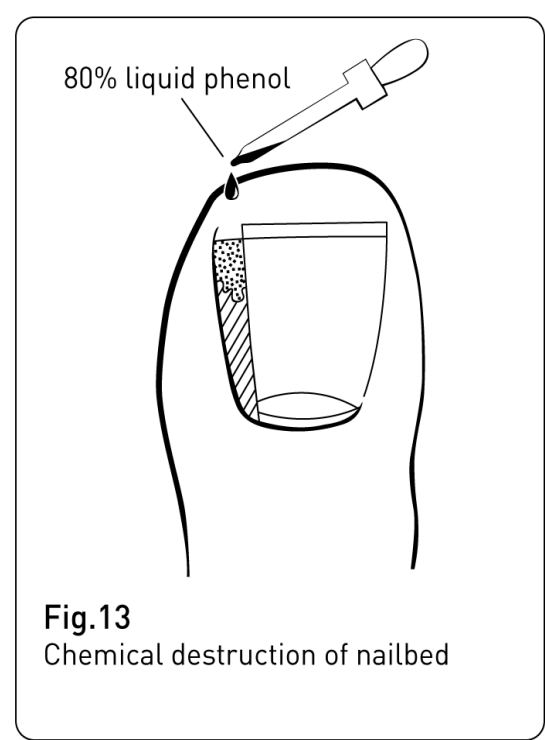




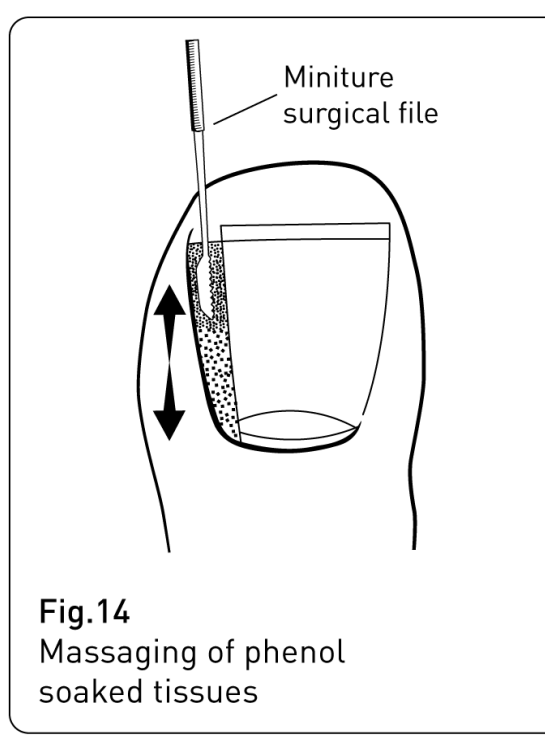
The open wound of the nail border is thoroughly dried and the section of removed nail plate is checked to insure that its root is intact. This simple step can be missed. Ripped or torn roots are a known cause for regrowth to occur.

80% strength liquid phenol is then applied to the exposed nail bed tissues (Fig 13). This chemical application is carried out at least twice during the procedure with additional massaging of the phenol soaked tissues using a miniature surgical file (Fig 14), giving particular attention to the germinating matrix tissue.

Once completed, the rubber bandage is removed and the circulation noted to return. An antiseptic compression dressing is applied and the patient instructed on after care with emphasis on foot elevation above the hip for the remainder of the day. The patient is also instructed on twice-daily saline footbaths and strong antiseptic redressing. Healing time is approximately 4 weeks.



**Fig.13**  
Chemical destruction of nailbed

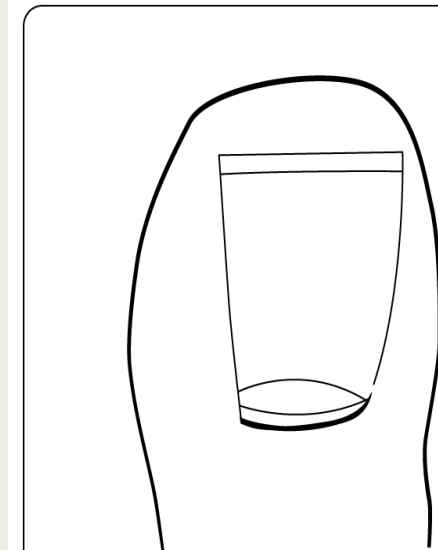


**Fig.14**  
Massaging of phenol soaked tissues

When healed the toenail is narrower and over the next several months the soft flesh reforms itself into a new nail border (Fig 15). Results look so good that it is difficult to see where the surgery took place but by comparing one toe with its opposite number on the other foot the difference in width is the only telltale sign.

**REMEMBER**

Normal and healthy toenails should not hurt. As a podiatric surgeon I recommend early care at even the slightest sign of trouble as the best action to maintain good health of your toenails.



**Fig.15**  
Healed, permanently narrower toenail

Mr. Scullion is a podiatric surgeon. He guest lectured for 10 yrs for the MSc in Sports Medicine at Trinity College Dublin. He is consultant and director for Biomechanics Foot Laboratory Ltd., and has been in private practice in The Castleknock Clinic, 23 Castleknock Avenue, Laurel Lodge, Castleknock, Dublin 15 since 1984.

His clinic telephone number is 8211347

His web page is [www.castleknockclinic.ie](http://www.castleknockclinic.ie)

His laboratory web page is [www.biomechanicsfootlab.com](http://www.biomechanicsfootlab.com)